

**Gurdev Parmar ND¹, FABNO, Erin Rurak ND¹, & Ferdinand Buencamino MD¹
Integrated Health Clinic, Fort Langley, British Columbia¹**

**CASE STUDY: UROTHELIAL CARCINOMA MANAGEMENT USING INTEGRATED
HEALTH CLINIC APPROACH**

Introduction:

Bladder cancer is the most common malignancy of the urinary system and the ninth most common malignancy worldwide¹. It is a major cause of morbidity, mortality and health-related costs. Urothelial carcinoma is by far the most common histologic type in the developed world where it accounts for roughly 90% of all bladder cancers. Less commonly, urothelial cancers can arise in the renal pelvis, ureter, or urethra. Environmental exposures, primarily smoking and occupational exposures are responsible for most cases of urothelial carcinoma². There have been no major advances in the development of new systemic therapies for urothelial carcinoma for over two decades, which may in part be related to the lack of comprehension of its pathogenetic mechanisms³. The overall prognosis of urothelial carcinoma is good; however, nearly half of all cases will recur within 2 years, and up to one-quarter of cases will progress to muscle-invasive disease, which is associated with a poor prognosis⁴. Studies have noted positive tumor response to several integrative modalities including hyperthermia, and specific targeted nutraceuticals used for chemoprevention. In this report, we present a case of urothelial carcinoma treated at the Integrated Health Clinic (IHC) that responded well to advanced naturopathic protocols including disease-specific dietary, supplementary, and intravenous therapies, as well as hyperthermia.

Case history:

D.A. is a 58 year-old male who has been diagnosed with urothelial carcinoma. Initial symptoms occurred roughly 7 years ago, well before any professional consultation, when DA noted macroscopic hematuria. D.A. sought consultation from his family physician who as part of his work-up, included a CT scan of the Intravenous urography (IVU) in March 2008. The scan revealed a polypoid bladder mass measuring 2.3 cm within the left posterior base of the bladder. There was no transmural spread noted, nor evidence of pelvic or retroperitoneal lymph node involvement. A cystoscopy was performed and the bladder tumor was removed via a transurethral resection of bladder tumour (TURBT). The pathology showed urothelial carcinoma in situ, flat type, and a high-grade sessile papillary urothelial carcinoma (Fig 1.).

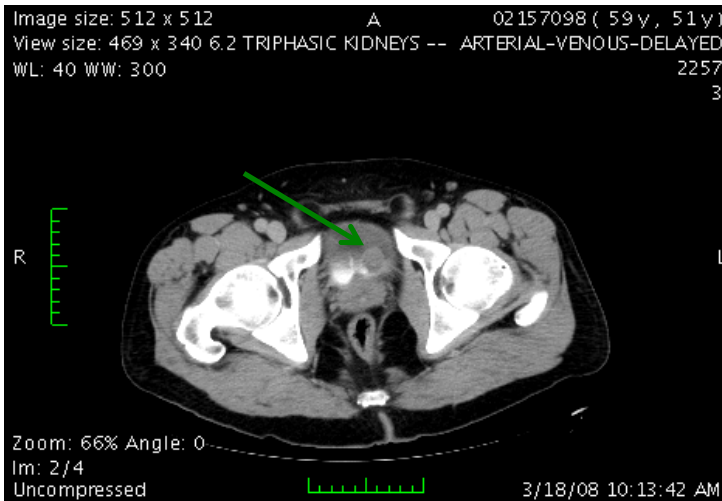


Figure 1. CT scan of IVU

He was recommended to undergo follow-up cystoscopies every 3 months. D.A. has had repeated recurrences of papillary tumors found in his bladder since 2008, having now undergone a total 20 cystoscopies and 7 resections and/or cauterizations over that time. In January 2015, a cystoscopy with biopsy was done and results showed a recurrence of high-grade sessile papillary urothelial carcinoma. It should also be noted that D.A. started 6 weekly Bacillus Calmette-Guérin (BCG) instillations in February 2015, which he completed on April 2015.

D.A. initially sought naturopathic consult on April 6, 2015 after completing his 6 weekly BCG installations to discuss integrative approaches to reduce the risk of recurrence of his bladder lesions and maintenance of BCG treatments, which at the time was not preventing recurrences. D.A. is a fit-looking gentleman who generally has a healthy lifestyle with no other physical complaints. He is a current non-smoker with a brief history of smoking of 4 years during adolescence.

D.A. was recommended the following naturopathic interventions with his ongoing standard of care (Table 1.)

Table 1. - Recommended Naturopathic Treatment Protocol

Medication	Dosage	Effect
Alpha-Lipoic Acid (ALAMax)	1 capsule p.o. BID	Induce apoptosis in cancer cells. Stabilize NF-κB transcription factor ⁵ . Inhibit proliferation of cancer cells by inhibiting glycolysis ⁶ .
Sulforaphane (Oncoplex)	2 capsules p.o. BID	Anti-proliferative in bladder carcinoma ⁷ . Induces Phase I and II enzymes involved in

		detoxification processes of chemical carcinogens ⁸ .
Fish oil (Ascenta)	1 tsp./day	Prevent progression of APPR and cachexia in weight losing patients with advanced cancer ⁹ . Induces cell cycle arrest and apoptosis by activating protein phosphatases ¹⁰ .
Curcumin	3,000mg daily in divided doses	Inhibit tumor initiation, promotion, invasion, angiogenesis, and metastasis ¹¹ . Inhibition of the transcription factor NF-κB to arrest tumor growth and its progression ¹²
IV Ascorbic acid (IVAA)	Once every 1-2 weeks	Improve quality of life, decrease tumor size and prolong relapse interval ¹³ . Alleviates cancer and chemotherapy related symptoms ¹⁴

In addition to his targeted treatments, D.A. was instructed to follow a low glycemic, whole foods diet with minimal refined sugars and flours, along with moderate exercise in the form of brisk walking. He was recommended loco-regional hyperthermia (LRHT) to the bladder and pelvis concurrently with IVAA (50 gms) and moving forward to coordinate with BCG treatments. D.A. received 8 LRHT treatments 2-3 times weekly to the pelvis without BCG instillations in the month of April 2015. He continues to receive the aforementioned I.V. infusions and targeted supplementation.

In May 2015, A CT of the abdomen and pelvis showed an irregular nodular thickening of the bladder, consistent with the patient's known bladder malignancy measuring 1.1 cm but with no enhancing renal mass (Fig 2.). A bladder biopsy performed on May 13, 2015 showed chronic inflammation with no evidence of malignancy. In August 2015, DA resumed his BCG instillations this time with LRHT. When combining LRHT with BCG, DA noted development of pelvic pain and gross hematuria, which he had not experienced previously with BCG. The symptoms occurred again after the second treatment. IV infusions and targeted supplementation was recommended to continue except for LRHT, which was discontinued upon patient's request.

D.A. had undergone 3 cystoscopies since and all revealed normal results. As noted earlier, previous cystoscopies showed a recurrence despite the use of BCG. With the addition of LRHT, 3 consecutive cystoscopies were all normal. He is currently on maintenance BCG infusions until June 2017. Judging from the imaging, laboratory results, and his signs and symptoms, his clinical course from the start of the treatment at IHC shows that there is no remaining evidence of disease, and that it has not progressed to any new sites.

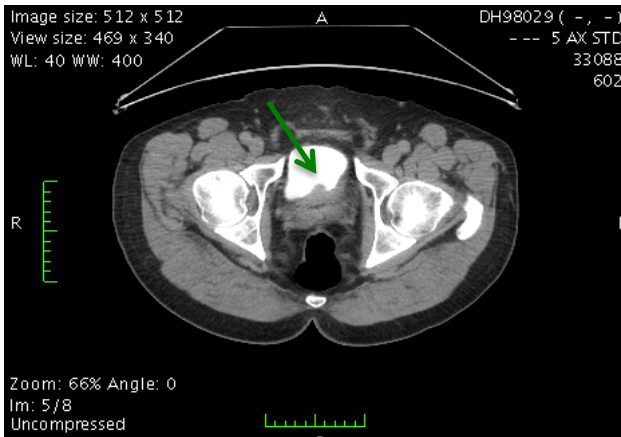


Figure 2. - CT of the abdomen and pelvis - May 2015

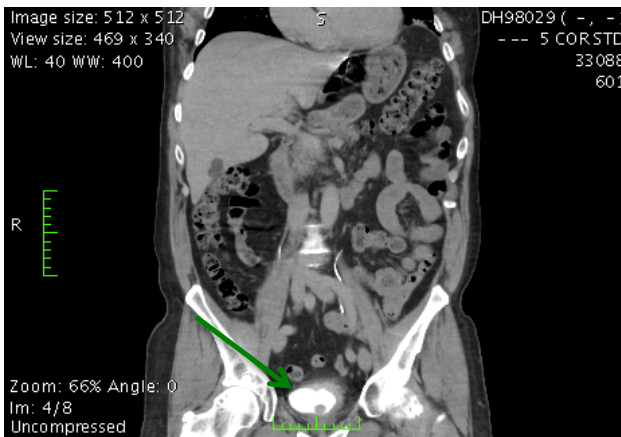

Figure 3. - CT of the abdomen and pelvis - May 2015

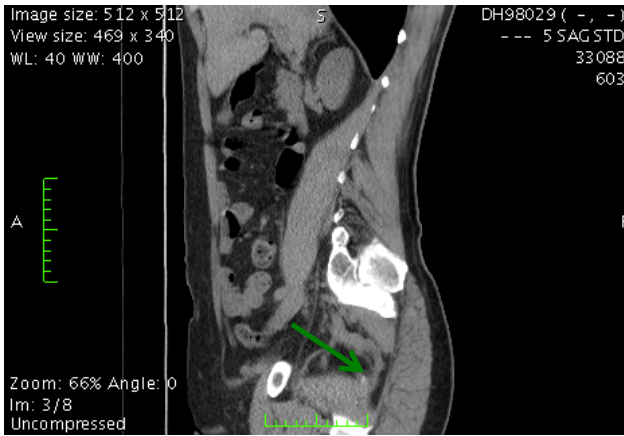


Figure 4. – CT of the abdomen and pelvis – May 2015

Discussion:

A major goal in the treatment of localized bladder cancer is reducing the risk of recurrences, which often occur repeatedly over many years, with multiple surgeries significantly reducing quality of life for patients as well as escalating health care costs. Immunotherapeutic agents such as bacillus Calmette-Guérin (BCG) are given intravesically and are generally considered first line adjuvant therapy after transurethral resection of bladder tumor (TURBT) for patients at intermediate or high risk of recurrence¹⁵. Intravesical chemotherapy is an alternative to BCG and likewise is effective in reducing tumor recurrences¹⁶. In recent years, bladder hyperthermia has been investigated as a means to enhance the delivery and effectiveness of chemotherapeutic agents to tumor cells inside the bladder. Over the past decade, three European trials have shown that moderate temperature (42-44°C) local bladder hyperthermia improves efficacy of intravesical chemotherapy^{17,18,19}. In an overview of methods for drug delivery to tumors, research shows that reduction of TIFP (Tumor Interstitial Flow Pressure) was temperature and time dependent. The reduction of TIFP was associated with an increase in perfusion and a sustained reduction of hypoxia, which led to an improvement in antitumoral effects when associated with chemotherapy and radiotherapy²⁰. Hyperthermia relies on the unique characteristics of malignant cells, and acts on these mechanisms to inhibit its growth. Compared to healthy tissue, malignant cells are more sensitive to high temperatures. Tumor cell architecture and vasculature is more chaotic compared to healthy tissue, and this leads to an immature, structurally defective microvascular system that is less resilient to perfusion shifts. The morphology, membrane fluidity and gene expression of a cancer cell also differs from normal cells. Heat increases membrane fluidity and instability of cancer cells, leading to cell death directly or indirectly through increased delivery of cytostatic chemotherapy agents. Heat induces expression of

p53, a tumor suppressor transcription factor that is mutated or decreased in cancer cells. Hyperthermia also induces protective anti-tumor immune responses by presenting the tumour peptides to naïve T-cells in the draining lymph nodes. The lymphocytes will mature and proliferate into cytotoxic T lymphocytes and CD4+ helper cells, mounting an adaptive immune response against tumour cells²¹. Elevated temperatures influence lymphocyte transformation and mitogenesis, both of which increase the activity of the immune system. The systemic activation of the immune system by hyperthermia may help target metastatic tumour cells²². DA clinically showed the benefits hyperthermia with improvement of symptoms. This case report shows the safety and efficacy of integrative oncology treatment for urothelial carcinoma. The long-term progress of the patient clearly shows the benefit of hyperthermia when it is used in conjunction with conventional therapy.

Conclusion

We presented a case of urothelial carcinoma. This case report shows that integrative oncology treatment is safe and may be effective for the management of urinary bladder cancer. The use of naturopathic treatment played an important role in the management of the patient's condition, wellness and quality of life. Urothelial carcinoma, being a recurrent disease should be managed using all possible resources. LRHT and IVAA in combination with BCG and targeted supplementation have been shown to be effective in the management of urothelial carcinoma.

References

- ¹ M Hammad Ather, Syed M Nazim. New and contemporary markers of prognosis in nonmuscle invasive urothelial cancer. *Korean J Urol.* 2015 Aug; 56(8): 553–564.
- ² Steineck G, Plato N, Norell SE, Hogstedt C. Urothelial cancer and some industry-related chemicals: an evaluation of the epidemiologic literature. *Am J Ind Med.* 1990;17:371-391.
- ³ Grivas PD1, Melas M2, Papavassiliou AG3. The biological complexity of urothelial carcinoma: Insights into carcinogenesis, targets and biomarkers of response to therapeutic approaches. *Semin Cancer Biol.* 2015 Aug 22. pii: S1044-579X(15)00069-3.
- ⁴ Chade DC, Shariat SF, Godoy G, Meryn S, Dalbagni G. Critical review of biomarkers for the early detection and surveillance of bladder cancer. *J Mens Health.* 2009;6:368–382.
- ⁵ Berkson B, Rubin D, Berkson A. The long term survival of a patient with pancreatic cancer with metastases to the liver after treatment with intravenous Alpha-lipoic acid/Low Dose naltrexone protocol.
- ⁶ Feuerecker B1, Pirsig S1, Seidl C1, Aichler M2, Feuchtinger A2, Bruchelt G3, Senekowitsch-Schmidtke R1. Lipoic acid inhibits cell proliferation of tumor cells in vitro and in vivo. *Cancer Biology & Therapy* 13:14, 1425–1435; December 2012; © 2012 Landes Bioscience.
- ⁷ Tang L, Zirpoli GR, Guru K, Moysich KB, Zhang Y, Ambrosone CB, McCann SE. Intake of Cruciferous Vegetables Modifies Bladder Cancer Survival Cancer. *Epidemiol Biomarkers Prev.* 2010 Jun 15.
- ⁸ Figueiredo S, Bindaa N, Nogueira-Machadoa J, Vieira-Filho S, Caligiornea R. The Antioxidant Properties of Organosulfur Compounds (Sulforaphane). *Recent Patents on Endocrine, Metabolic & Immune Drug Discovery* 2015, 9, 000-000
- ⁹ Barber M, Ross J, Preston T, Shenkin A, Fearon K. Fish oil-enriched nutritional supplement attenuates progression of the acute-phase response in weight-losing patients with advanced pancreatic cancer. *J Nutr* 1999-129-1120.
- ¹⁰ Siddiqui R, Shaikh S, Sech L, Yount H, Stillwell W, Zaloga G. Omega 3-Fatty Acids: Health Benefits and Cellular Mechanisms of Action. *Mini reviews in Medicinal Chemistry.* 4(8):859-871.
- ¹¹ Frenkel M, Abrams D, Ladas E, et. Al. Integrating Dietary Supplements into Cancer Care. *Integrative Cancer Therapies* 12(5) 369-384.
- ¹² Banerjee S1, Chakravarty AR1. Metal Complexes of Curcumin for Cellular Imaging, Targeting, and Photoinduced Anticancer Activity. *Acc Chem Res.* 2015 Jul 21;48(7):2075-83.
- ¹³ Fritz H1, Flower G2, Weeks L2, Cooley K3, Callachan M1, McGowan J1, Skidmore B1, Kirchner L4, Seely D5. Intravenous Vitamin C and Cancer: A Systematic Review. *Integr Cancer Ther.* 2014 May 26;13(4):280-300.
- ¹⁴ Carr A1, Vissers M1, CookJ2. The effect of intravenous vitamin C on cancer and chemotherapy-related fatigue and quality of life. Department of Pathology, Centre for Free Radical Research, University of Otago, Christchurch New Zealand.

¹⁵ Malmstrom PU, Sylvester RJ, Crawford DE, Friedrich M, Krege S, Rintala E, et al. An individual patient data meta-analysis of the long-term outcome of randomised studies comparing intravesical mitomycin C versus bacillus Calmette-Guerin for non-muscle-invasive bladder cancer. *Eur Urol*.2009;56(2):247–56.

¹⁶ Abern M, Owusu R, Anderson M, Rampersaud E, Inman B. Perioperative intravesical chemotherapy in non-muscle-invasive bladder cancer: a systematic review and meta-analysis. *J Natl Compr Canc Netw*. 2013;11:477–84.

¹⁷ Colombo R, Da Pozzo LF, Salonia A, Rigatti P, Leib Z, Baniel J, et al. Multicentric study comparing intravesical chemotherapy alone and with local microwave hyperthermia for prophylaxis of recurrence of superficial transitional cell carcinoma.[see comment] *Journal of Clinical Oncology*. 2003;21(23):4270–6.

¹⁸ Gofrit ON, Shapiro A, Pode D, Sidi A, Nativ O, Leib Z, et al. Combined local bladder hyperthermia and intravesical chemotherapy for the treatment of high-grade superficial bladder cancer. *Urology*.2004;63(3):466–71

¹⁹ Lammers RJ, Witjes JA, Inman BA, Leibovitch I, Laufer M, Nativ O, et al. The role of a combined regimen with intravesical chemotherapy and hyperthermia in the management of non-muscle-invasive bladder cancer: a systematic review. *Eur Urol*. 2011;60(1):81–93.

²⁰ Baronzio G, Parmar G, Baronzio M. Overview of methods for overcoming hindrance to drug delivery to tumor, with special attention to tumor interstitial fluid. *Front Oncol*. 2015 Jul 23;5:165.

²¹ Parmar G, Rurak E. A Promising Cancer Therapy. *NDNR Hyperthermia* 2001 Feb.

²² Parmar G, Habib C. Hyperthermia in Oncology. *JHP*, November/December 2012